

# Evaluation of PTEN: Immunohistochemical Analysis of Tissues and Cells

Angela Lightbown, Katherine Crosby, Qingfu Zeng, Michael Lewis and Bradley L. Smith, Cell Signaling Technology, Inc, Beverly MA

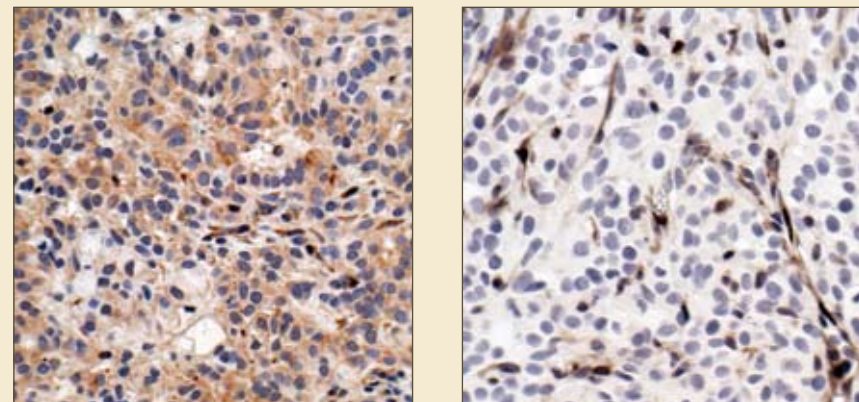
## Introduction

PTEN is a lipid and protein phosphatase that is frequently mutated in cancer. In addition, PTEN has been identified as a key inhibitor of the PI-3-kinase AKT survival pathway in tumors. Therefore, characterization of PTEN expression in patient tumor samples is an important factor in predicting potential patient response to targeted therapeutics and in the development of combinations of therapeutics intended to overcome drug resistance. In this study we optimized PTEN IHC staining on wild type and mutant PTEN cell pellets, xenografts and patients samples in tissue arrays. We observed that PTEN staining may be sensitive to variation in tissue handling or fixation as indicated by a relationship between negative PTEN staining and negative Vimentin staining in normal tissues in screens of tissue micro-arrays. PTEN staining may also be affected by antigen retrieval method. These results suggest that further study is required before reliable PTEN analysis may be routinely performed on patient samples.

## Methods

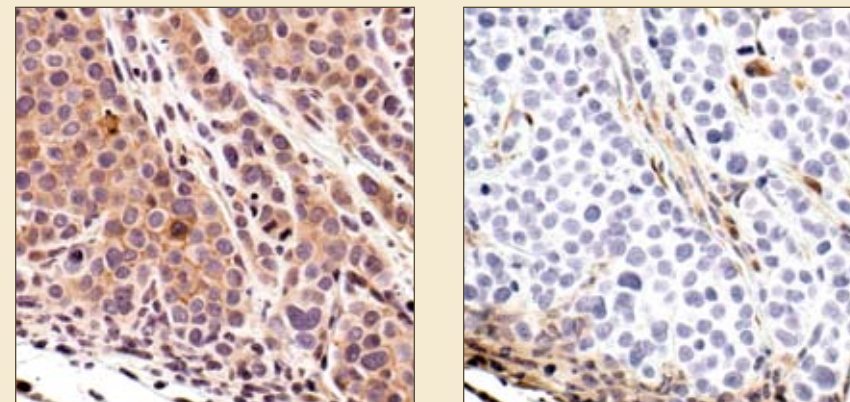
Western blot and Immunohistochemistry were performed according to CST standard protocols, with primary incubations overnight at 4°C. Staining was performed using CST's PTEN Antibody (# 9559), p-AKT(Ser 473) Antibody (# 3787). Vimentin staining was performed using NeoMarkers 3B4 Vimentin Antibody (# MS-1818) using trypsin antigen retrieval. Cell pellets were fixed in 10% NBF, then processed and embedded per standard procedures. Xenografts were initiated using 5-10 x10<sup>6</sup> cells in 50% Matrigel™ and fixed for 24, 48 or 72 hours in 10% NBF.

## PTEN Antibody Staining of PTEN Positive and Negative Xenografts



IHC of paraffin embedded xenografts, demonstrating the specificity of PTEN Antibody. A549 cell line (left) is PTEN positive, U87-MG cell line (right) is PTEN negative.

## PTEN v. p-Akt (Ser473) on MDA-MB 468 Xenograft



IHC of paraffin-embedded MDA-MB-468 xenograft, using p-Akt (Ser473) Antibody (left) or PTEN Antibody (right). MDA-MB-468 cells lack PTEN. Note the lack of PTEN staining in the Phospho-Akt positive cells.

## IHC Assessment of Sample Quality: PTEN and Vimentin v. Various Phospho-antibodies in FFPE Tissue Arrays

	Vimentin (-)	p-Tyrosine (-)	p-Akt (-)	p-EGFR (-)
PTEN (-)	88%	90%	98%	99%
99 cases	87 cases	89 cases	87 cases	98 cases

	PTEN (-)	p-Tyrosine (-)	p-Akt (-)	p-EGFR (-)
Vimentin (-)	44%	72%	91%	97%
196 cases	87 cases	141 cases	179 cases	191 cases

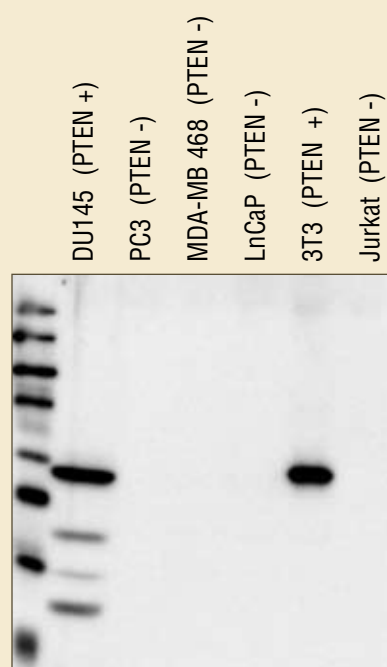
## PTEN IHC Optimization on Cell Pellets

Cell Line: H358: PTEN Positive					
	Antibody Dilution				
Antigen Retrieval	1:50	1:100	1:200	-Ab	
Citrate	+++	++	++	-	
EDTA	+++	+++	++	-	
Trypsin	++	+	+	+	

Cell Line: LNCaP: PTEN Negative					
	Antibody Dilution				
Antigen Retrieval	1:50	1:100	1:200	-Ab	
Citrate	+	-	-	-	
EDTA	+	+	+	+	
Trypsin	+++	++	++	-	

Cell Line: H1650: PTEN Negative					
	Antibody Dilution				
Antigen Retrieval	1:50	1:100	1:200	-Ab	
Citrate	-	-	-	-	
EDTA	-	-	+	-	
Trypsin	++	+	+	-	

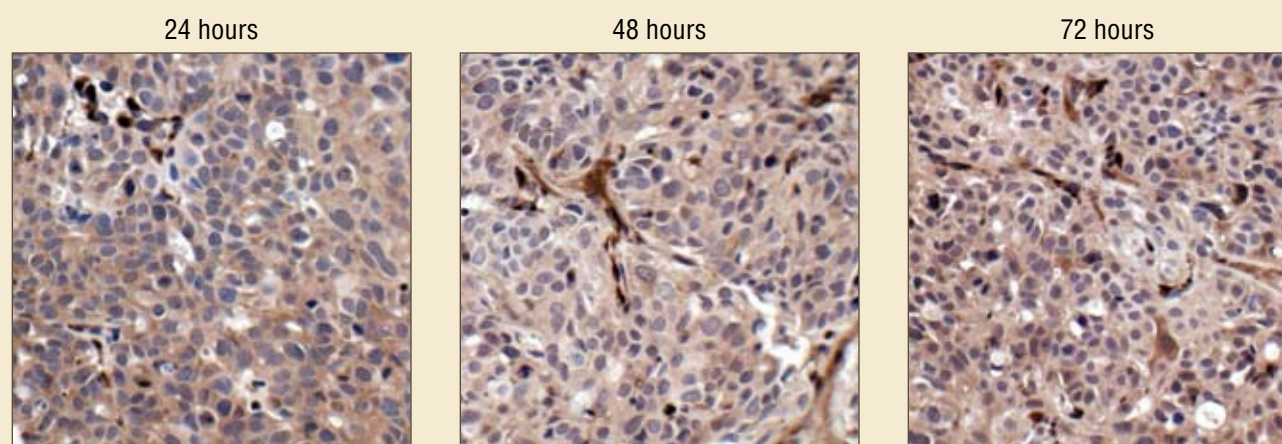
Comparative staining scores of various antigen retrieval methods and antibody dilutions on PTEN positive and negative cell pellets.



Western blot analysis of PTEN positive and negative cell lines using PTEN Antibody.

## DU145 Xenograft: Time of Fixation

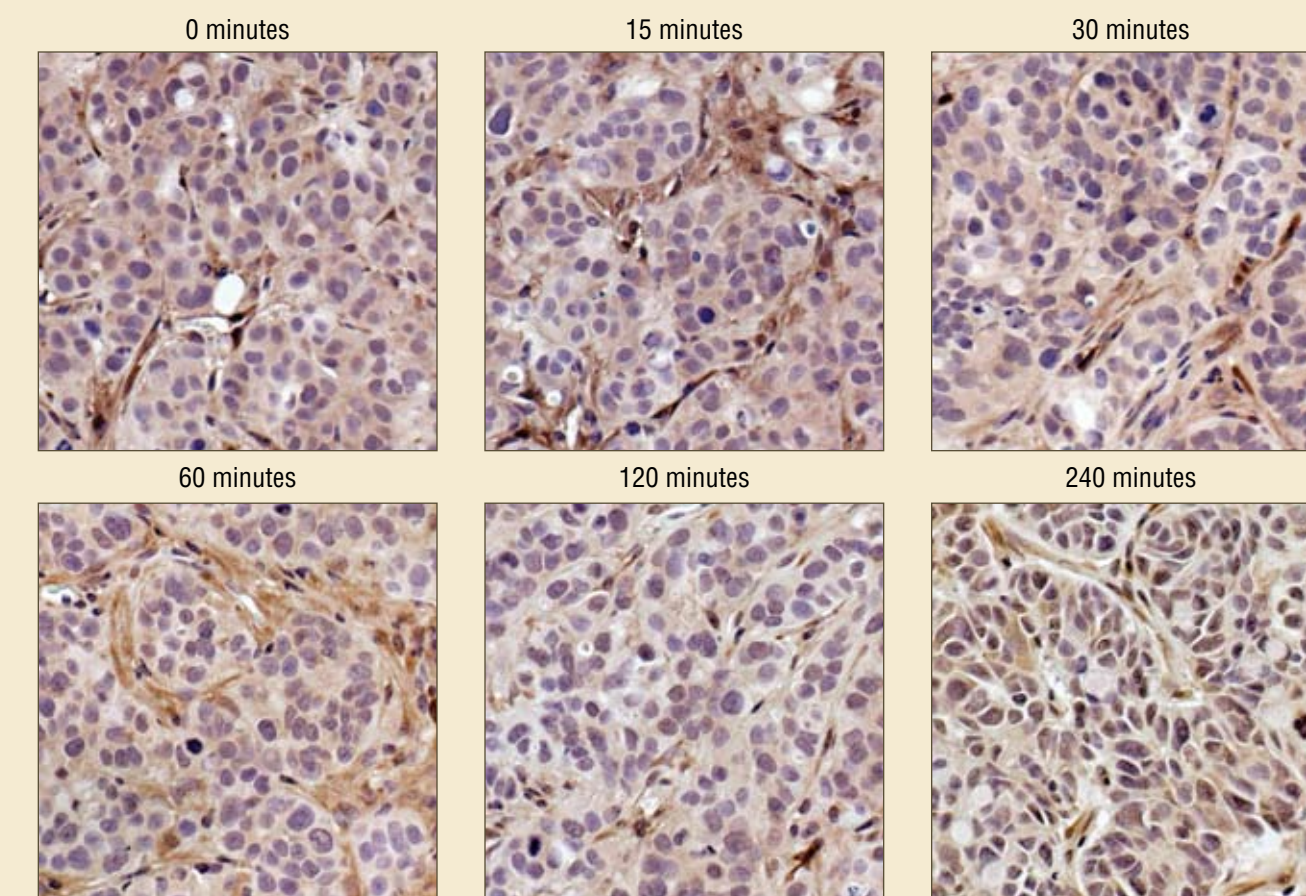
Time of Fixation (hrs)	Score of IHC Staining Intensity	
	Cancer Cell	Stromal Cell
24	+++	+++
48	+++	+++
72	+++	+++



IHC of DU145 xenografts fixed in 10% NBF for 24, 48 or 72 hours, using PTEN Antibody.

## HT-29 Xenograft: Time Before Fixation

Time Before Fixation (min)	Score of IHC Staining Intensity	
	Cancer Cell	Stromal Cell
0	++	+++
15	++	+++
30	++	+++
60	+ / ++	+ / +++
120	+ / ++	++
240	+	+



IHC of HT-29 xenografts using PTEN Antibody. Tumors remained on benchtop for various times between 0 minutes and 240 minutes prior to fixation in 10% NBF.

## Summary

- Well validated PTEN characterization is needed to conduct reliable expression studies on patient samples.
- PTEN staining was affected significantly by antigen retrieval method. Optimal staining conditions were determined to be 1:100 antibody dilution, using Citrate pH 6.0 as antigen retrieval buffer.
- Negative PTEN staining strongly associated with lack of stain for p-EGFR, p-Akt and p-Tyr-100. PTEN negative staining clearly indicated that antigenic reactivity in those tissue blocks was weakened.
- The relationship between PTEN and significant signaling markers was closer than that of Vimentin and those same markers.
- In our experiments, time of fixation up to 72 hours did not have a negative effect on PTEN IHC results. Time before fixation greater than one hour did negatively affect IHC staining.
- PTEN may be a better indicator of poor tissue quality than Vimentin.